

STUDIES IN EXPERIMENTAL EXTRACORPOREAL THROMBOSIS.

II. THROMBUS FORMATION IN NORMAL BLOOD IN THE EXTRACORPOREAL VASCULAR LOOP.

BY TAKUJI SHIONOYA.*

(From the Division of Medicine, Mayo Clinic, and the Mayo Foundation, Rochester, Minnesota.)

PLATE 1.

(Received for publication, April 6, 1927.)

A study of thrombosis necessitates a consideration of the theory of the clotting of blood. In this country, Howell's theory of coagulation is accepted almost exclusively. It is not my desire to enter into controversial matters either in regard to the mechanism of clotting or to the origin and nature of platelets. Howell's theory may be readily recalled from the following schema.

Coagulation Factors in the Circulating Blood:

Prothrombin, from platelets.

Antiprothrombin (heparin), from liver.

Calcium.

Fibrinogen.

The Mechanism of Clotting.—Cellular elements yield thromboplastic substances.

Thromboplastic substance neutralizes antiprothrombin.

Prothrombin + calcium = thrombin.

Thrombin + fibrinogen = fibrin = clot.

From the following investigations it will be evident that the deposition of platelets and the liberation of fibrin may occur as two distinct though probably related phenomena. By the method employed it is possible to study these factors separately.

The methods employed by Zahn (6), Pitres (3), Bizzozero (1), Eberth and Schimmelbusch (2, 4) for the study of experimental

* Fellow of the Rockefeller Foundation.

thrombosis had involved observations on the mesenteric vessels of living animals after the vessels have been injured chemically or mechanically. Welch (5) used dogs chiefly, and produced thrombi of the femoral vessels and jugular vein by various procedures, such as the application of caustics, the introduction of foreign bodies and mechanical injuries. While all these methods offer excellent opportunities for the examination of injuries of very small parts of the vessels, repeated serial sections, especially during the short period of the first stage of thrombosis, are precluded, unless more than one vessel is brought into the study. With the method of investigating extracorporeal thrombosis, described in Paper I of this series, the mode and mechanics of thrombus formation, the structure of thrombi and the effects of mechanical, chemical and physical and pathologic factors on thrombus formation can be readily investigated.

Before discussing in detail the various investigations on factors influencing experimental extracorporeal thrombosis, the formation of thrombi in normal blood in the extracorporeal circulation must be discussed briefly.

EXPERIMENTAL STUDIES.

Experiments were performed according to the description in Paper I of this series, and throughout this work the same individual apparatus has been used constantly. As soon as the clamps on the vessels are released, a violent stream of blood enters the apparatus through the arterial cannula, and returns to the jugular vein by means of the venous cannula, after having passed through a collodion dialyzing tube which is immersed in a physiologic solution of sodium chloride at body temperature. Pulsations of the blood stream, eddies, currents and whirls can be easily observed through the glass and collodion walls. This is most striking in the wider part of the arterial cannula, as the stream reaches this point only after passing through the constricted part of the cannula. In the collodion tube also, streaming blood and pulsating movement can be seen before clotting occurs. Even after the latter has taken place, the pulsation of the collodion tube can be seen and felt at times. In 2 or 3 minutes a few white thrombi appear in the constricted part of the venous cannula and in the collodion tube and the blood clots quickly. This occurs also on the foreign surface

of the collodion tube and on the irregular surfaces of connecting parts of the tubing. In the collodion tube, which presents a greater caliber than other parts of the apparatus, the blood current is rather slower, the clotting begins as soon as small collections of platelets appear, and in some instances even begins before white thrombi form. At first, clotting is incomplete and leaves sufficient room for the stream to continue. White thrombi formed in the arterial part of the apparatus are dislodged by the violent current. These may lodge in the collodion tube, or be carried to the venous half of the apparatus and tend to gather especially in the constricted part of the venous cannula. The latter is an important factor in determining the duration of flow. Fibrin is formed around the platelet thrombi and soon the constricted part of the venous cannula is obstructed usually in from 4 to 10 minutes after the circulation is established (Fig. 1). Then the blood which is contained at rest in the venous half of the apparatus clots. The blood current thus becomes gradually slower and the white thrombi stick to the inner surfaces of the arterial cannula also. When complete obstruction occurs, the blood in the apparatus gradually darkens and no more ballooning of the jugular vein can be observed on clamping it below the cannula.

During the period of actual circulation, or after the obstruction is complete, the red thrombus begins to form in the jugular vein following the deposition of white thrombi in the constricted part of the venous cannula. These may grow rapidly, extending in the direction of the circulating blood. Within 30 minutes the red thrombus in the jugular vein may be 0.5 cm. long and as large as the caliber of the jugular vein. The intima of the vein may have been more or less injured by clamping or by insertion of the venous cannula, so that the thrombus may be definitely attached to the wall of the jugular vein. As the apparatus consists of sections, connecting parts leave irregular surfaces and white thrombi are formed; then fibrin forms around the thrombi; thus the mixed thrombus grows into the lumen.

More remarkable is the case in the collodion tube in the transition between the collodion tube and paraffined glass tubes. The white thrombi are laid down in ring form, at the junction of the glass and collodion tubes, where the lumen undergoes marked change. Fibrin forms in 2 or 3 minutes, and later, red clots attach to it. In other

wider parts of the tube, as soon as a few tiny white thrombi are produced, films of blood clot stick to the membrane successively. Thus a few minutes after obstruction, the collodion tube is almost filled with red clot.

In the serial sections stratification is seen in the red clot, that is, the clot is a mural red thrombus, quite flat, with a wide base developed from the tiny white thrombus. When the obstruction occurs very quickly, and the clotting time is very short, or when the blood stream is very slow, no white thrombi can be recognized. When the blood stream is very slow, the constricted part of the arterial cannula may be obstructed by white thrombi and the blood of the whole apparatus comes to standstill and clots as a column. White thrombi occasionally form in the carotid artery, starting from the injured intima or from the white thrombi in the constricted part of the arterial cannula.

Two of the seven normal rabbits weighed 2500 gm. each and presented large arteries and an unusually vigorous stream, so that circulation in the apparatus persisted for 30 minutes. In these two instances many rather large white thrombi appeared in almost all parts of the collodion tube and the venous part of the apparatus. While the vigor of the stream tends to prevent platelets from adhering to the abnormal surfaces of the apparatus and to prevent fibrin from being deposited on the surfaces of white thrombi, the stream in the venous cannula, on the other hand, is not powerful enough to wash away the white thrombi gathered there. The collodion tube in these animals presented a thin layer of clot at its bottom, and ring forms of large mixed thrombi at the points of connection. But true obstruction takes place always in the constricted parts of the cannulas sooner or later, owing to the mixed thrombi formed either in the venous or in the arterial cannula, the exact site depending largely on the vigor of the blood stream.

SUMMARY.

Thrombus formation has been studied in normal rabbits with an experimental method of establishing extracorporeal circulation. In the normal animal circulation in the extracorporeal loop usually ceases in from 6 to 10 minutes, or at most, in very large and vigorous

animals, in 25 minutes.¹ Cessation of the circulation is due most frequently to obstruction of the venous cannula (sometimes of the arterial cannula) by a mass of white thrombi and secondary fibrin formation around it. The site of the clot is determined somewhat by the swiftness of the blood stream.

In the collodion tube red mural thrombi are obtainable as a rule. They are flat and present a wide base resting on tiny white thrombi. After the complete obstruction of the circulation, the blood in the apparatus clots very rapidly. When the obstruction occurs very quickly either in the arterial or venous cannula, or when the blood stream is very slow, the clotting in the loop may occur before platelets are laid down in large numbers or before the formation of the white thrombi is evident.

Mixed thrombi are found in the jugular vein, and have their inception in the white thrombi, in the cannula or from the injured intima. They extend in the direction of the blood flow.

BIBLIOGRAPHY.

1. Bizzozero, J., Ueber einen neuen Formbestandtheil des Blutes und dessen Rolle bei der Thrombose und der Blutgerinnung, *Arch. path. Anat. u. Physiol.*, 1882, xc, 261.
2. Eberth, J. C., and Schimmelbusch, C., Experimentelle Untersuchungen über Thrombose, *Arch. path. Anat. u. Physiol.*, 1886, ciii, 39.
3. Pitres, A., Recherches expérimentales sur le mode de formation et sur la structure des caillots qui déterminent l'hémostase, *Arch. physiol. norm. et path.*, 1876, iii, series 2, 230.
4. Schimmelbusch, C., Die Blutplättchen und die Blutgerinnung, *Arch. path. Anat. u. Physiol.*, 1885, ci, 201.
5. Welch, W. H., The structure of white thrombi. Papers and addresses, Baltimore, 1920, i, 47.
6. Zahn, F. W., Untersuchungen über Thrombose, *Arch. path. Anat. u. Physiol.*, 1875, lxii, 81.

EXPLANATION OF PLATE 1.

FIG. 1. White thrombus mass with red clot in the venous cannula (in the case of normal blood at the end of 10 minutes). *a*, mass of white thrombi. *b*, red clot. $\times 100$.

¹This is true when only the side and corner tubes are paraffined. When all glass tubes are paraffined, circulation is maintained for a number of hours, as will appear in a future communication.

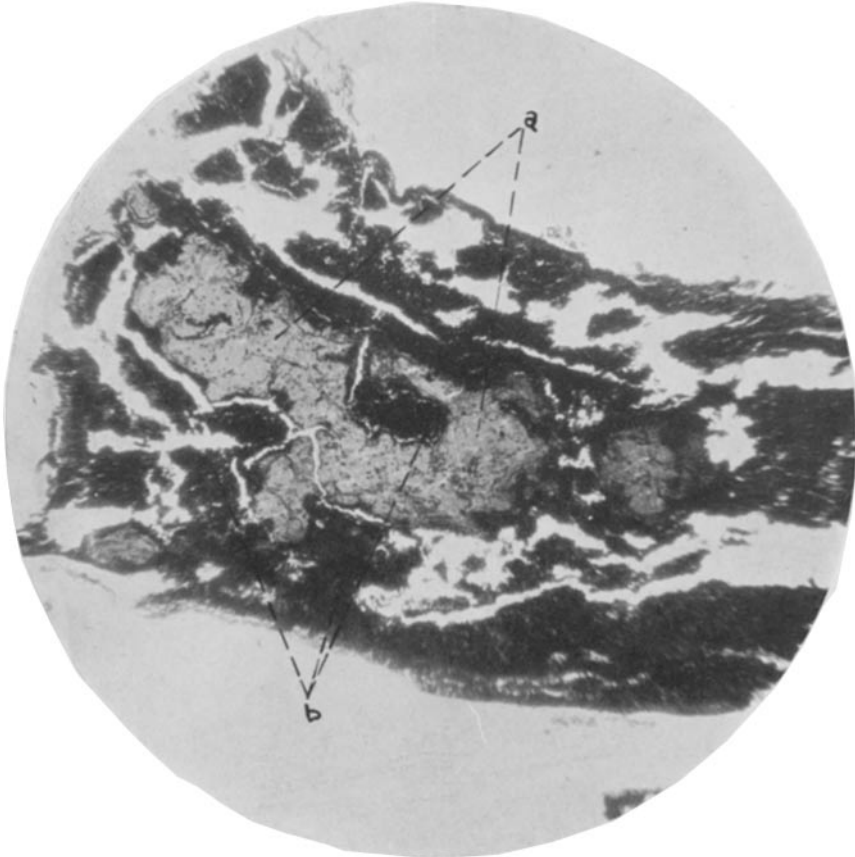


FIG. 1.

(Shionoya: Extracorporeal thrombosis, II.)